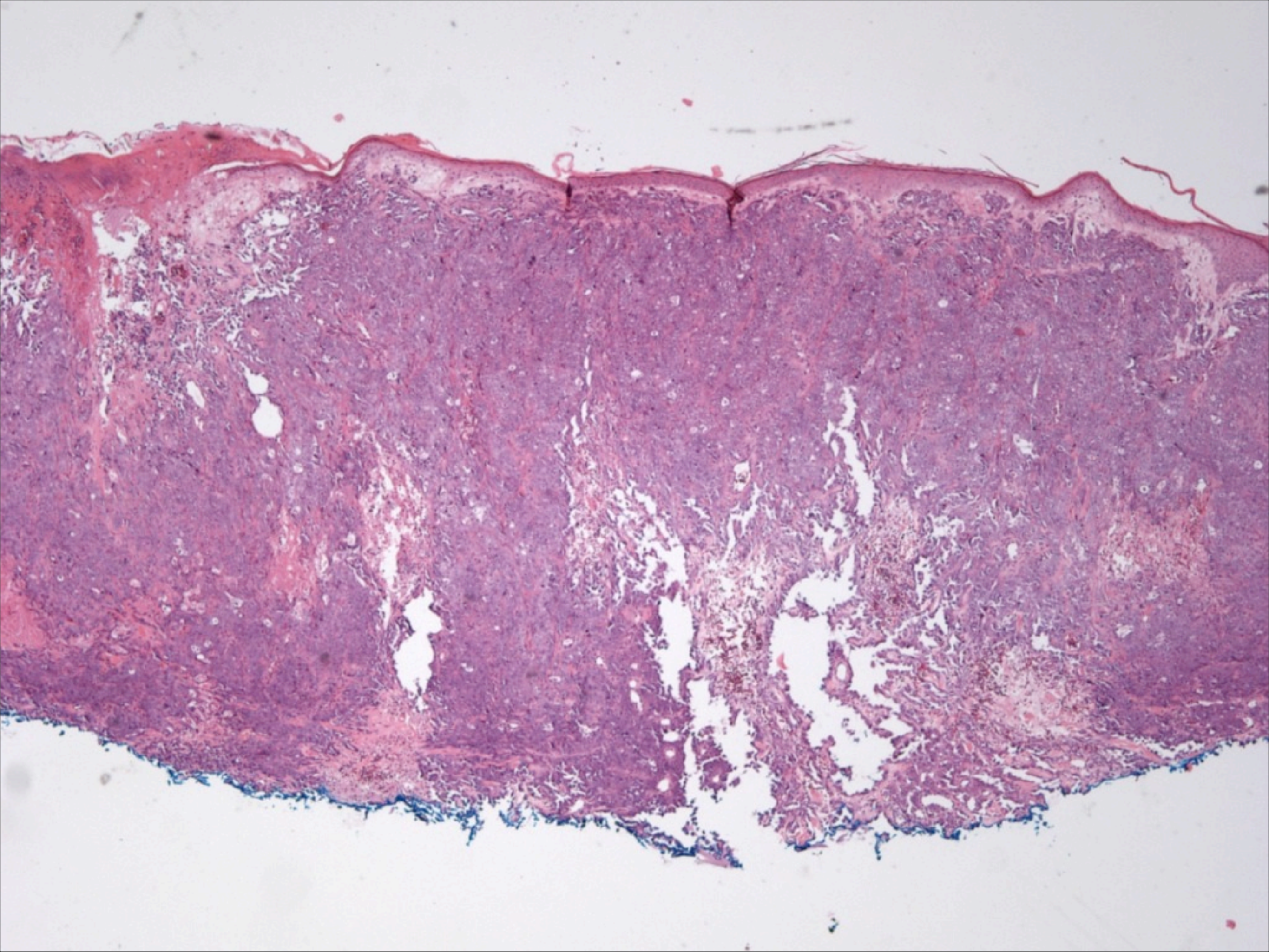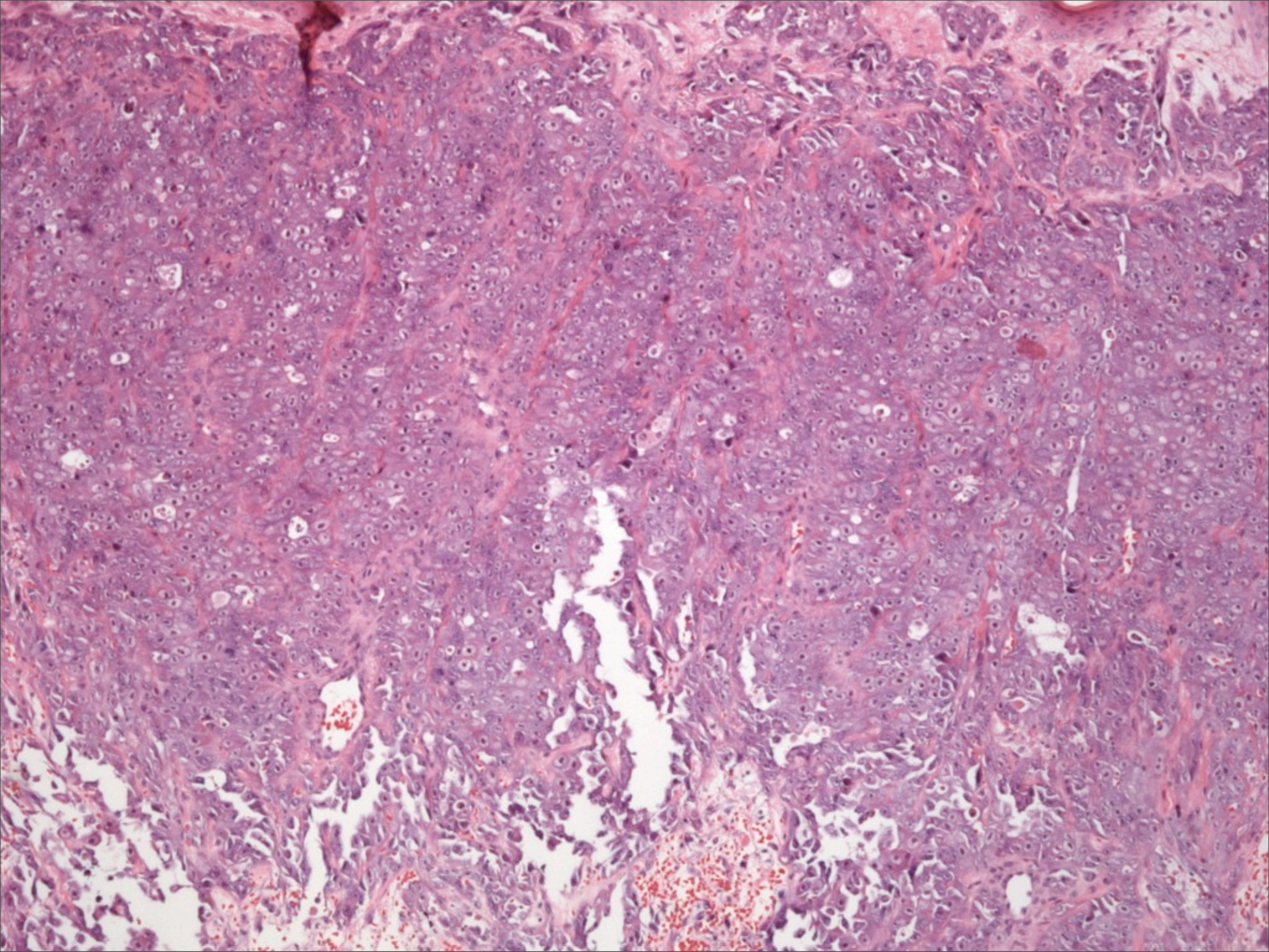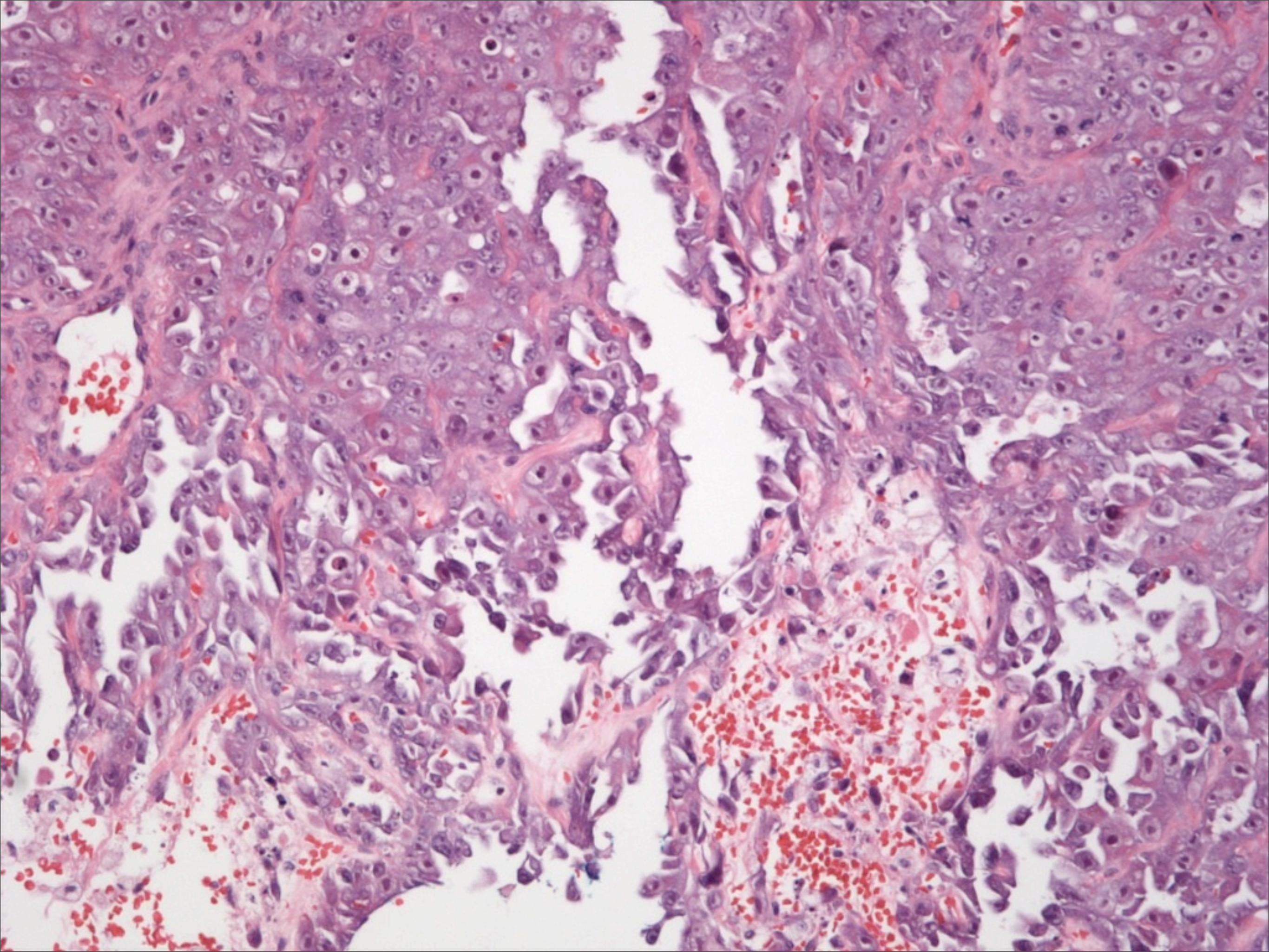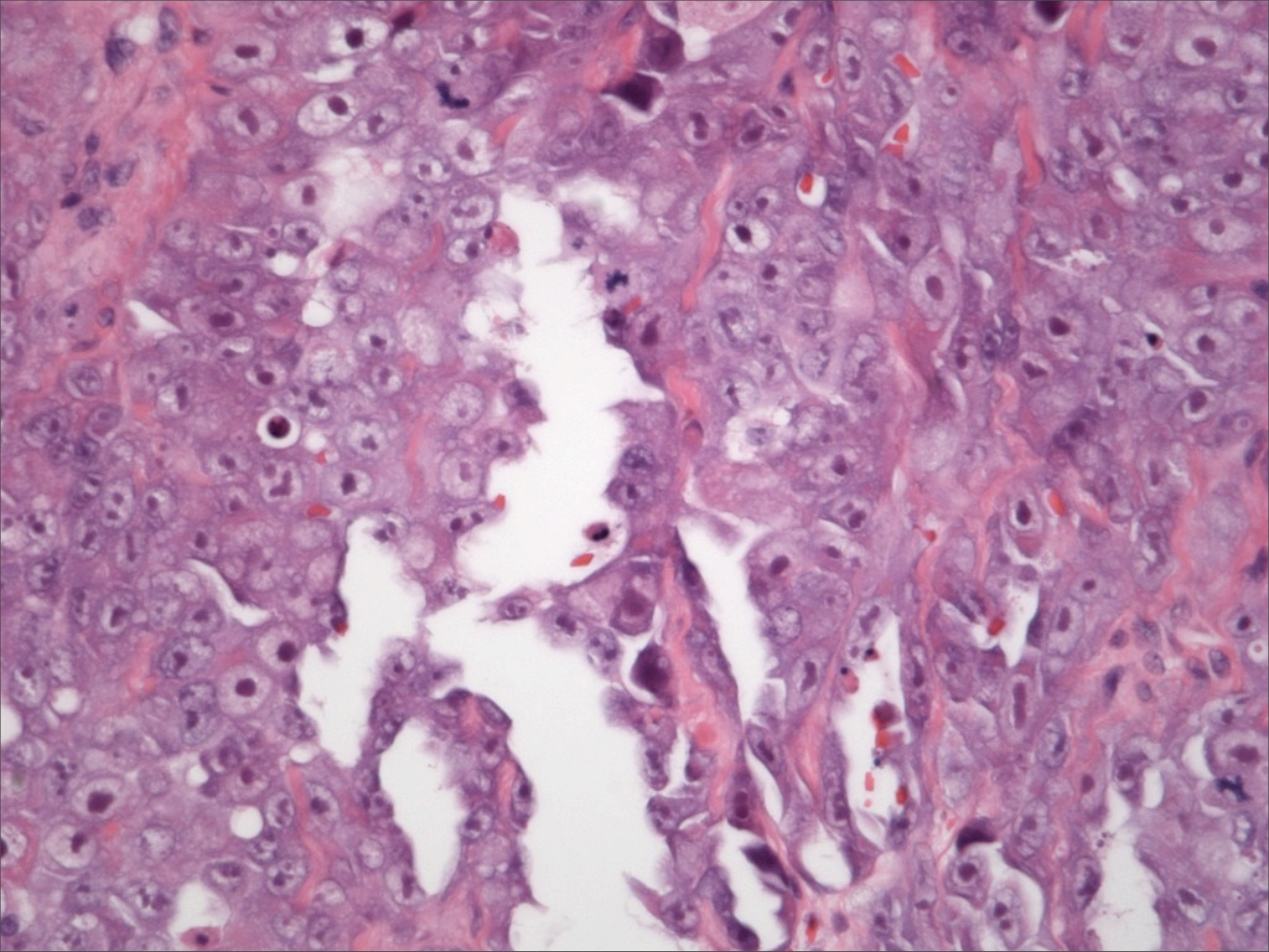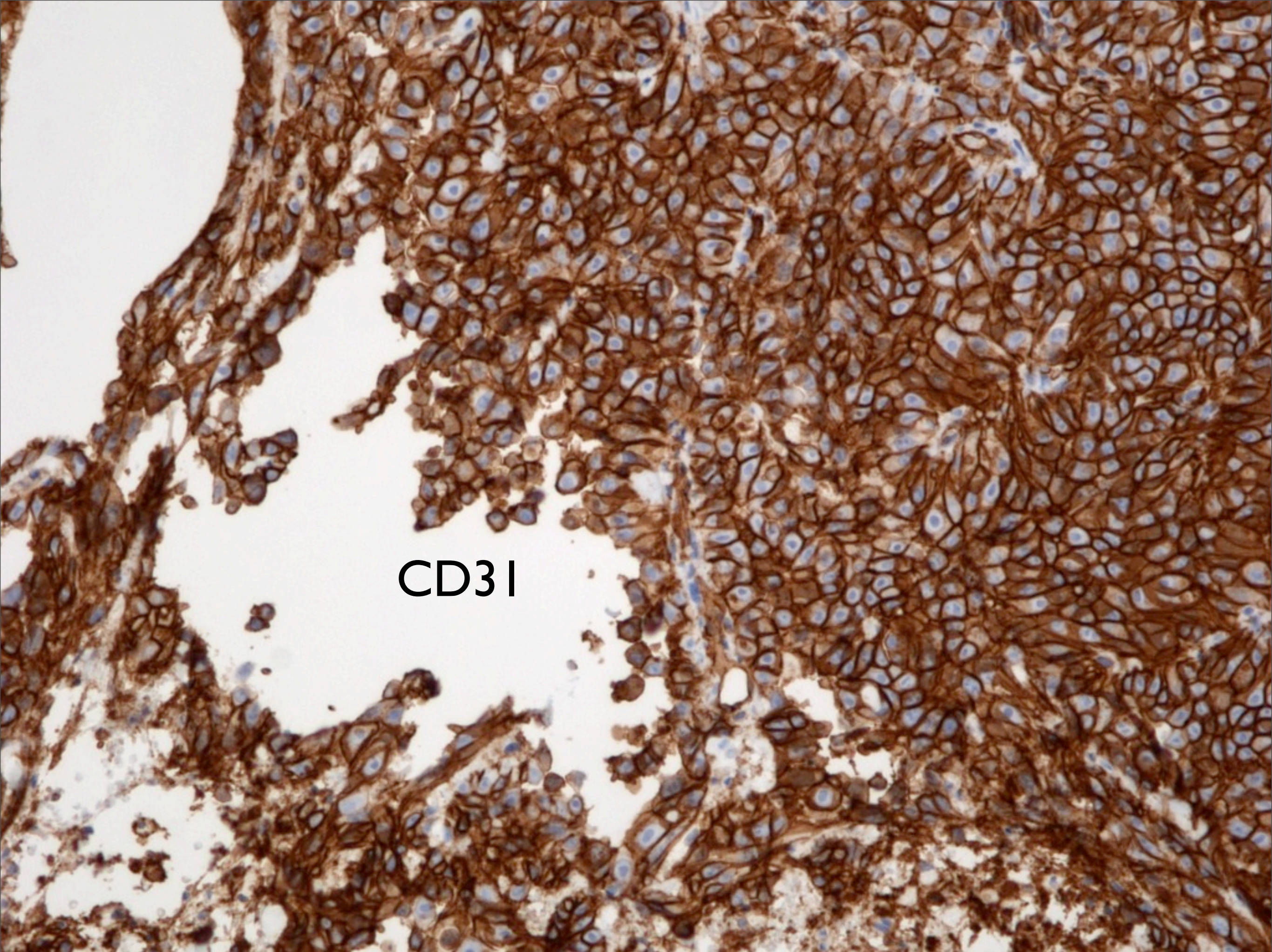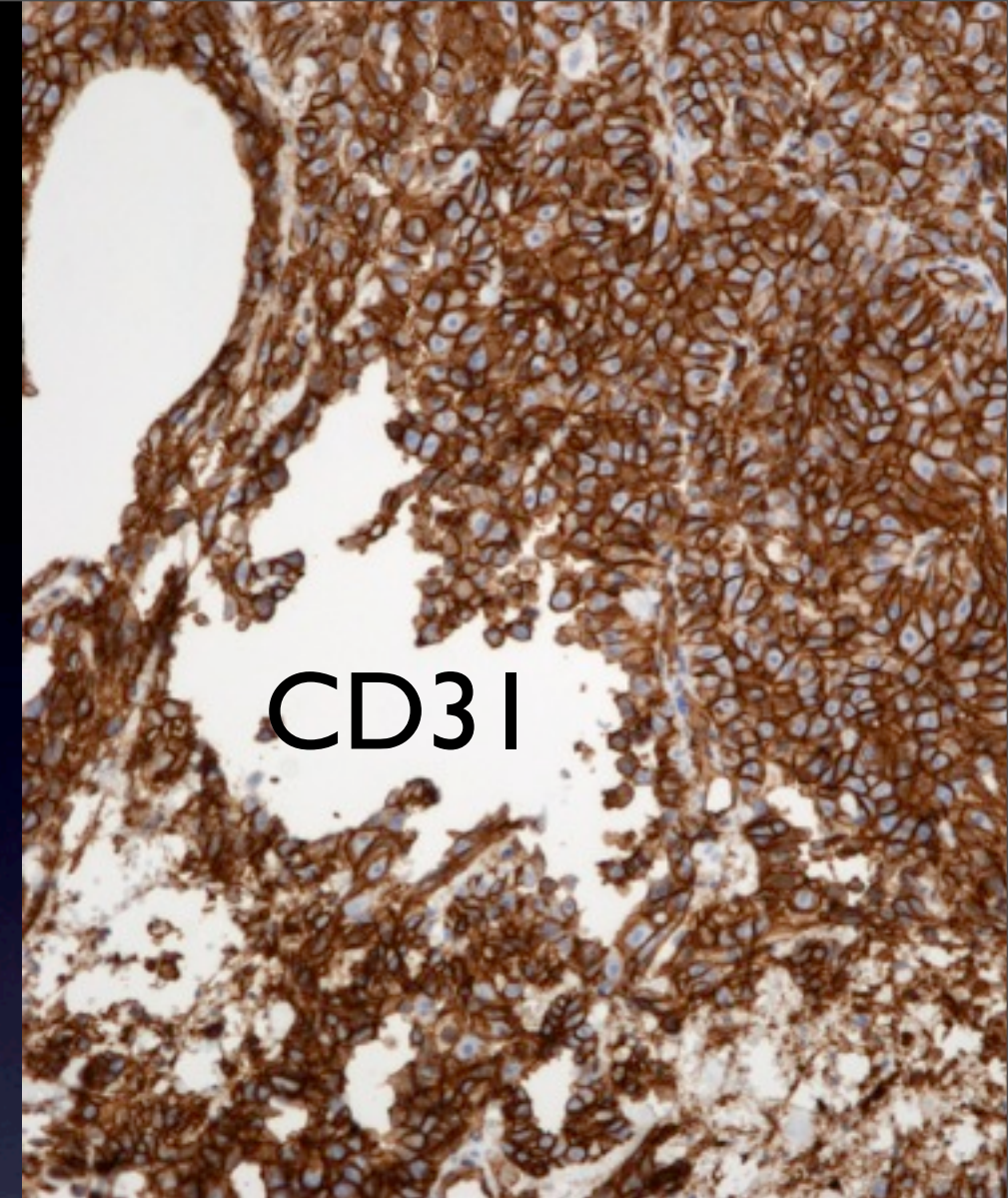
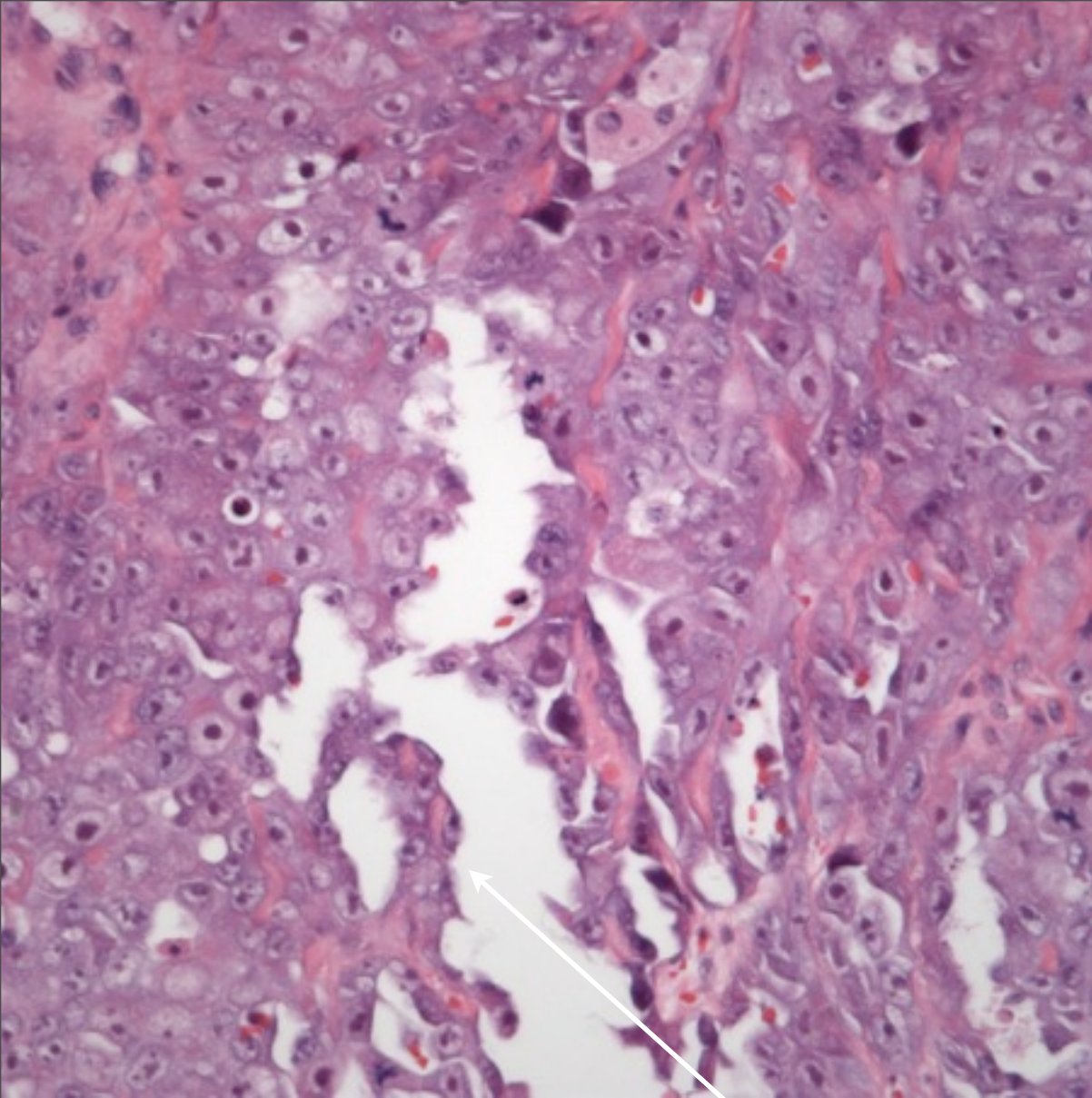


CD3 I



# Cutaneous Angiosarcoma





Pleomorphic cells with abortive vascular channels

Occasional “Blister cells “ with intracytoplasmic rbc

May need IHC confirmation

Rule out carcinoma, melanoma, or lymphoma